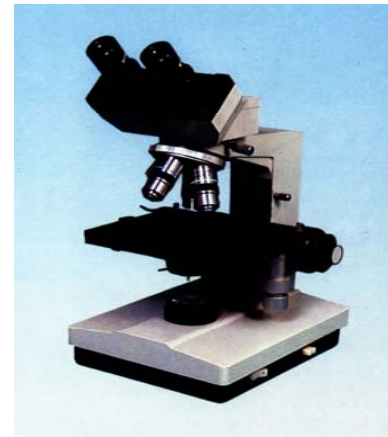



Histology and Embryology



- Chapter 1 Introduction and Cell**
- Chapter 2 Epithelial tissue**
- Chapter 3 Connective Tissue**
- Chapter 4 Blood**
- Chapter 5 Cartilage and Bone**
- Chapter 6 Muscle Tissue**
- Chapter 7 Nerve Tissue**
- Chapter 8 Circulatory System**
- Chapter 9 Immune System**
- Chapter 10 Skin**
- Chapter 11 Digestive Tract**
- Chapter 12 Digestive Gland**
- Chapter 13 Respiratory System**
- Chapter 14 Urinary System**
- Chapter 15 Endocrine System**
- Chapter 16 Sense Organ**
- Chapter 17 Male Reproduction**
- Chapter 18 Female Reproduction**
- [Chapter 19 Embryology 1](#)**
- Chapter 20 Embryology 2**

Chapter 19 Embryology 1

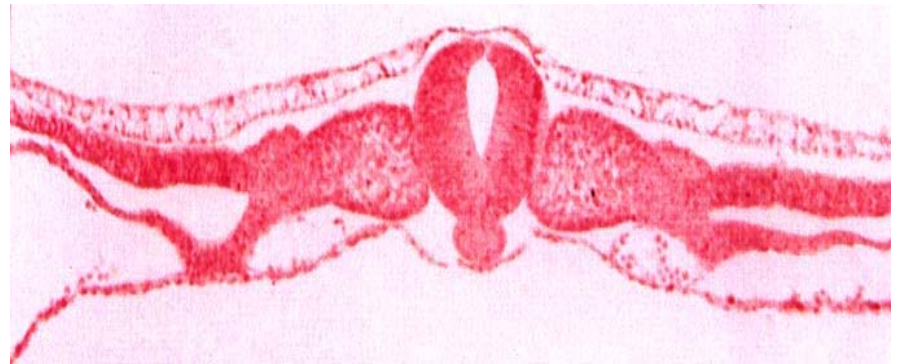I Slides

II Sections

NO.98 capacitation

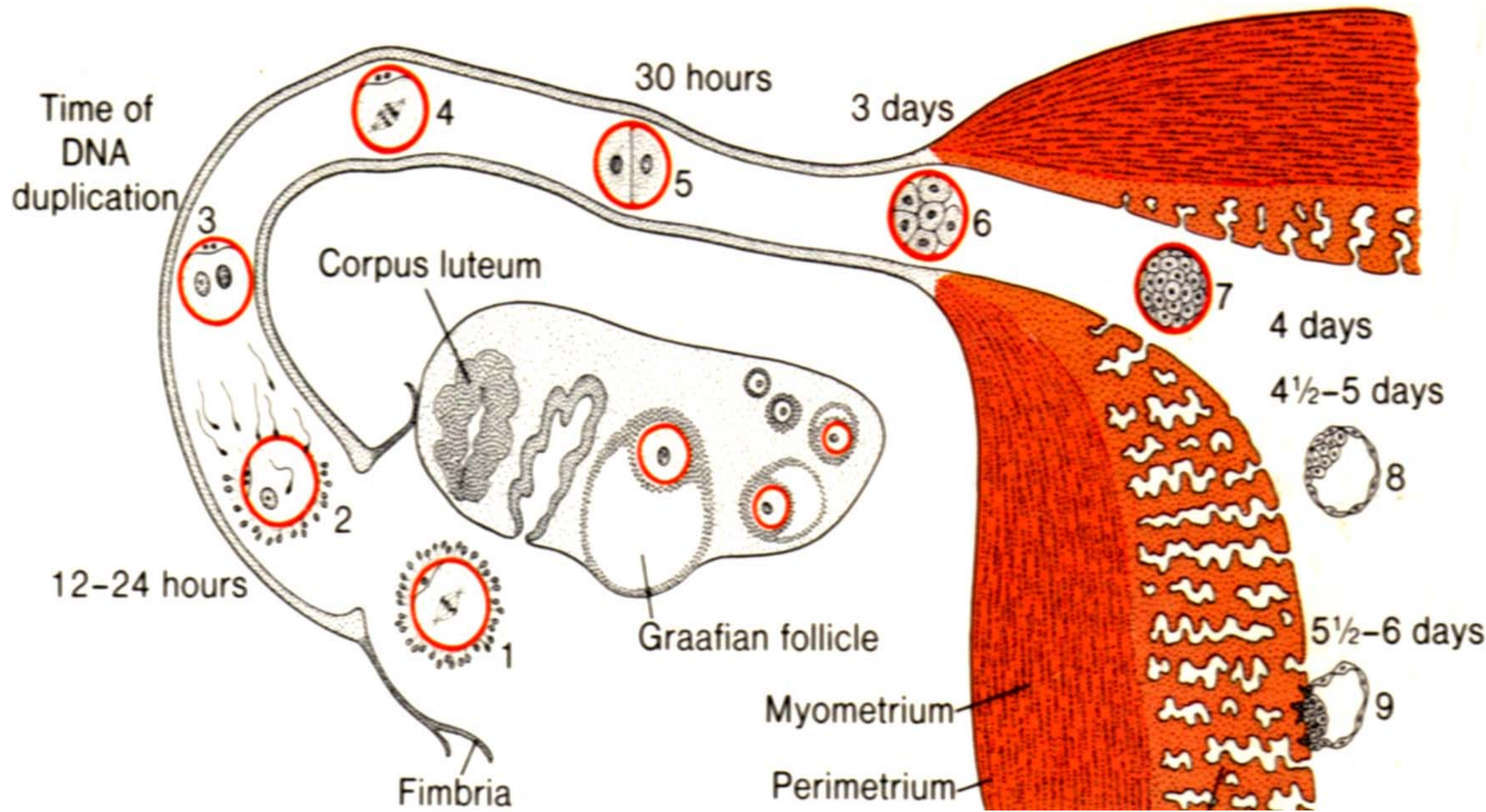
NO.99 placenta

NO.100 trilaminar germ disc

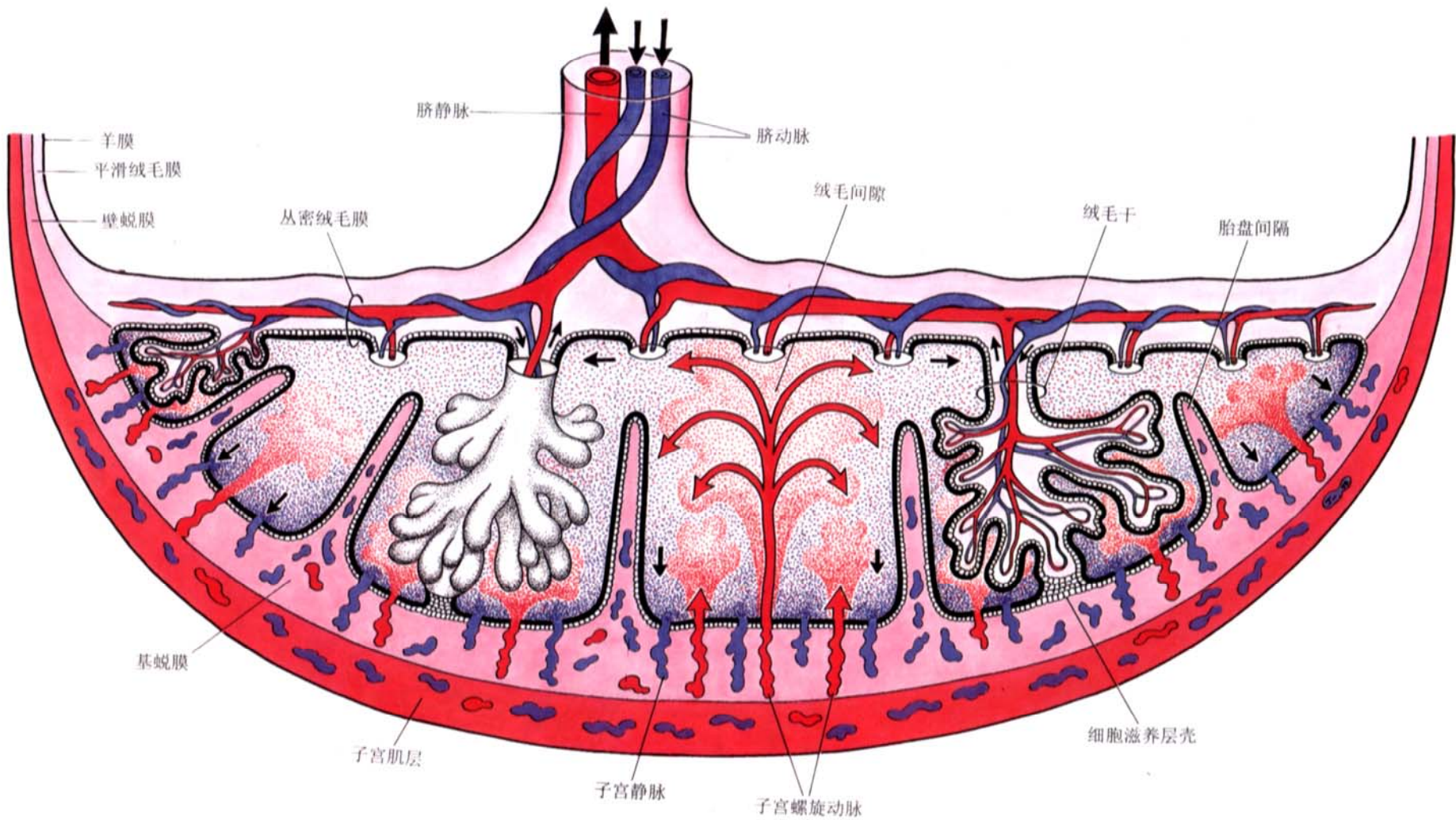


III EM photos : 69~72

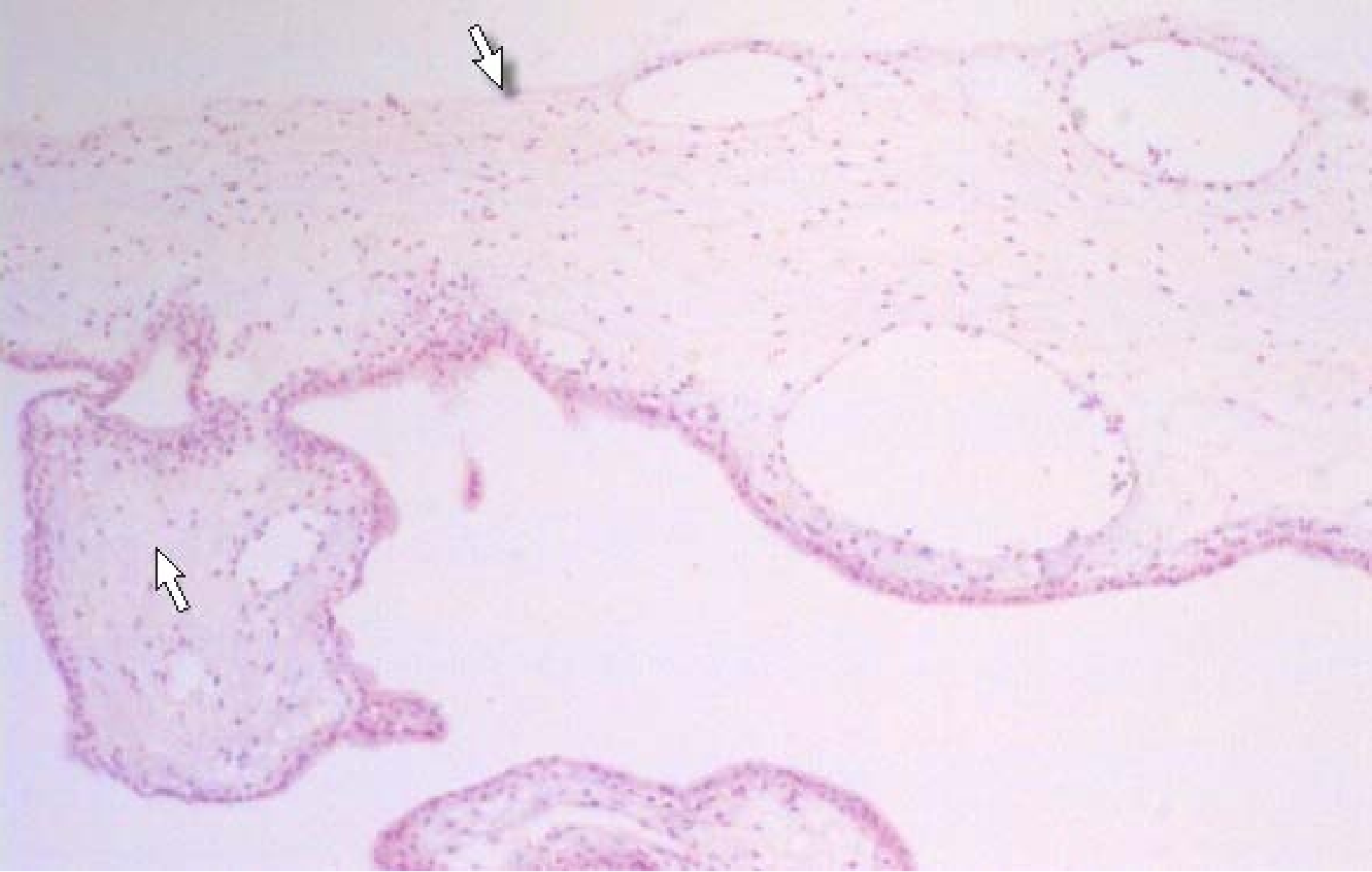IV Summary



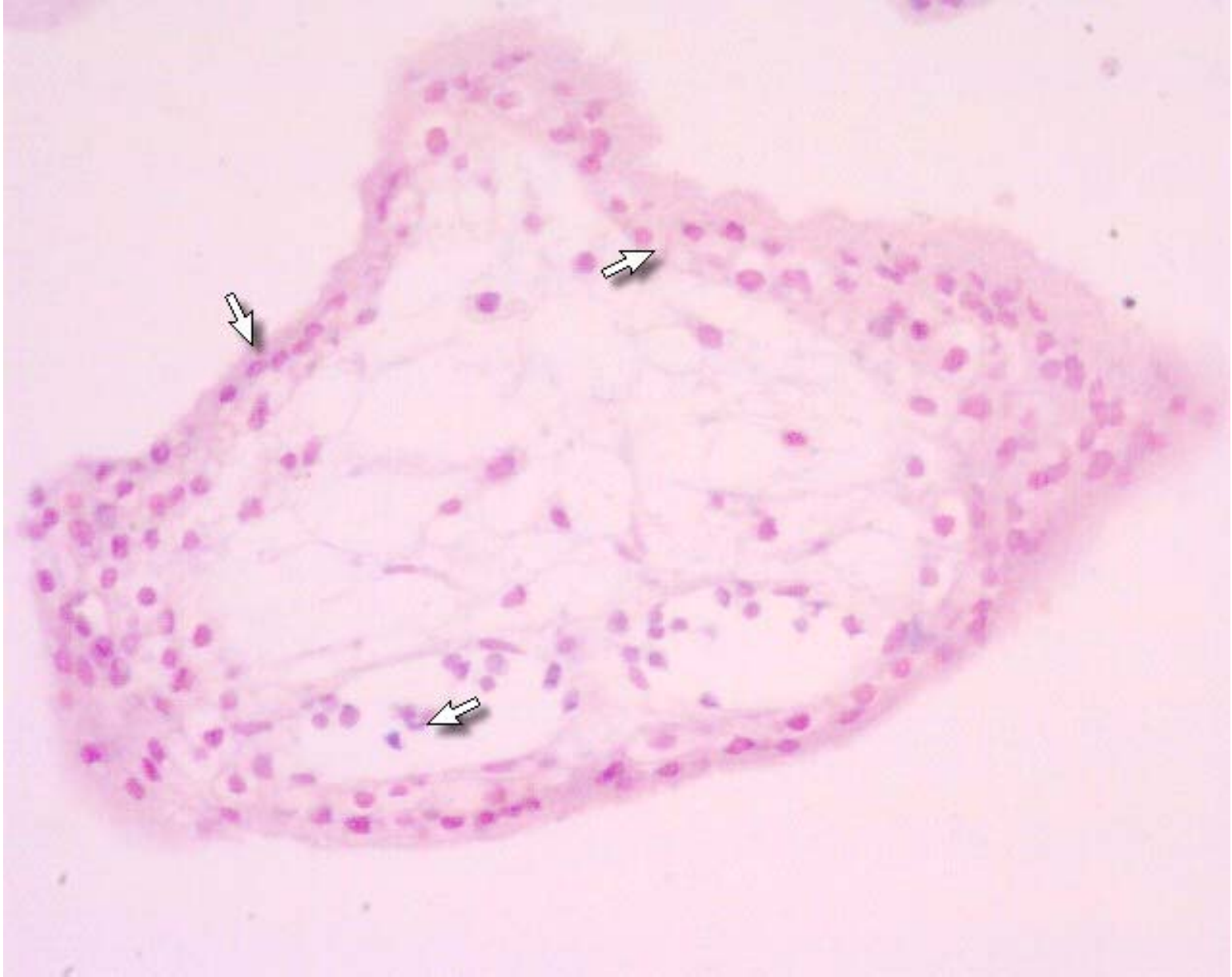
Preembryonic period



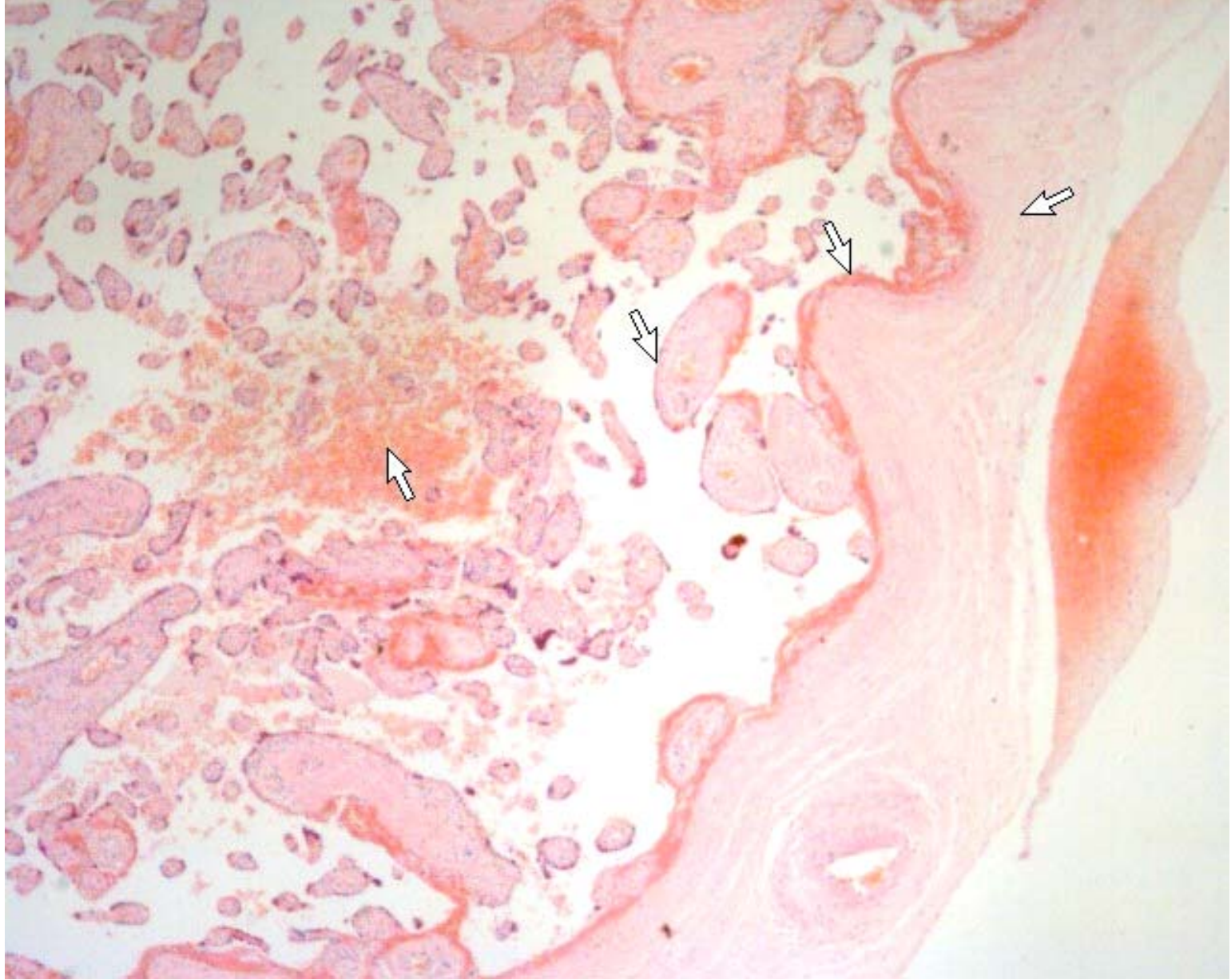
placental



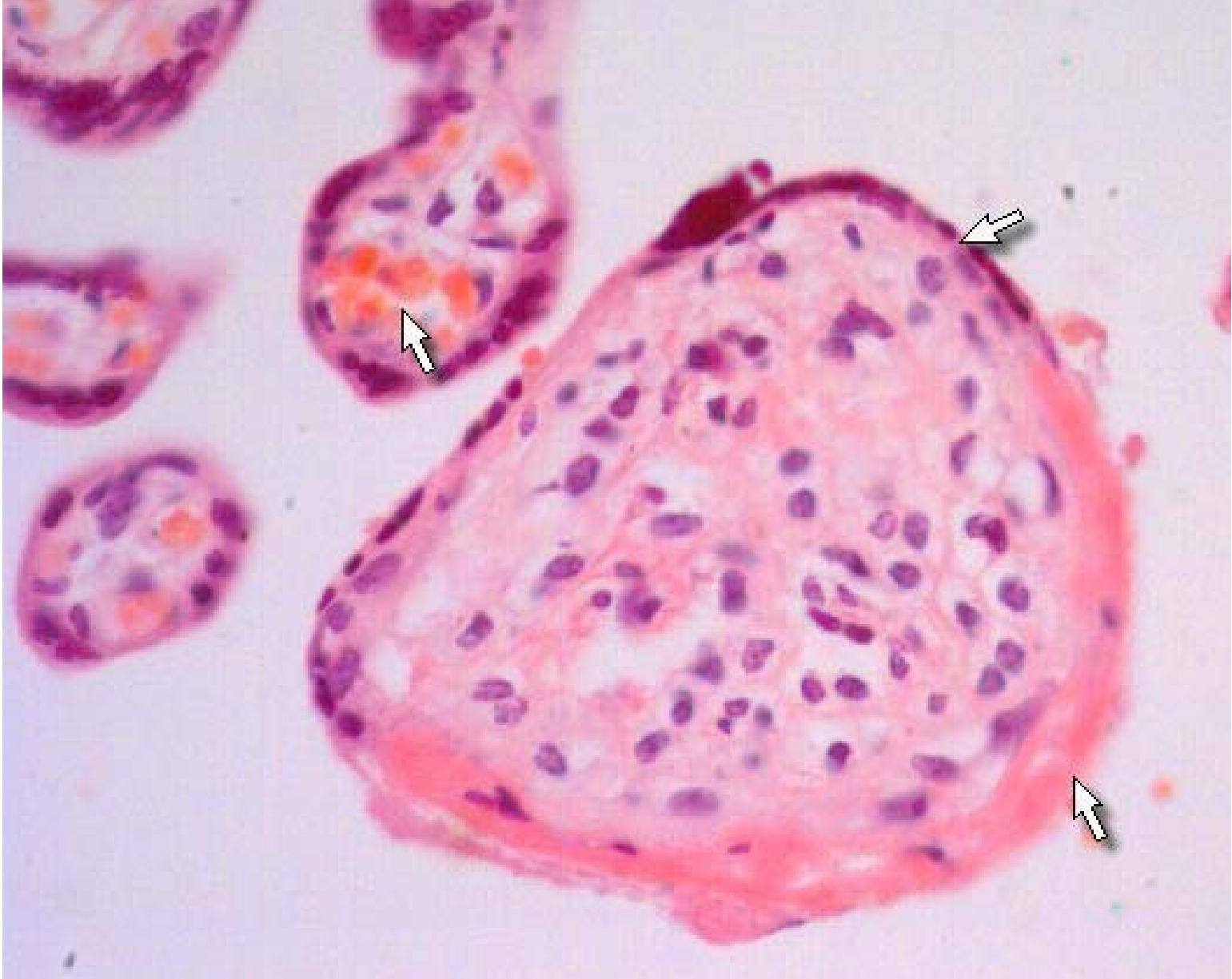Intervillous space



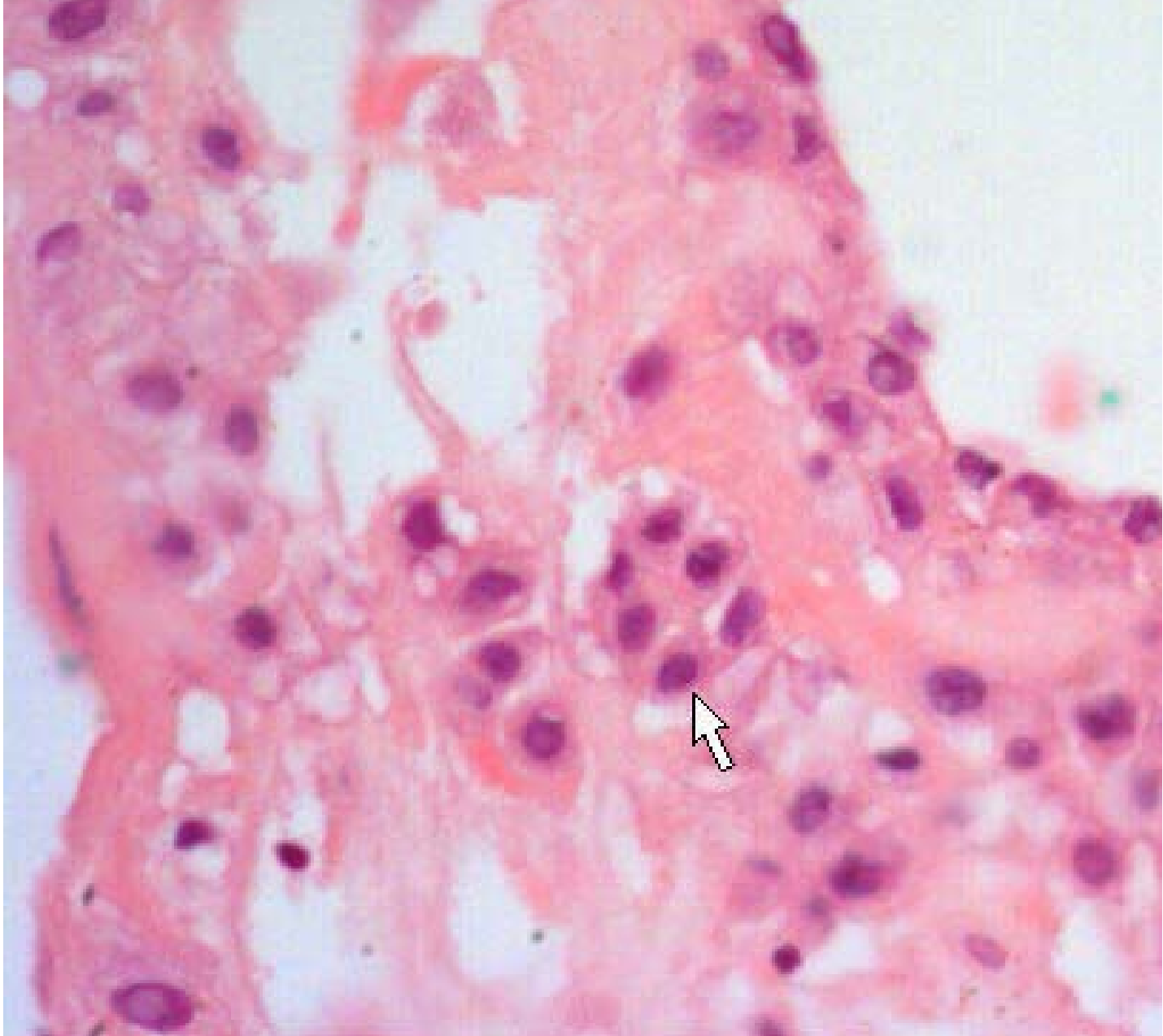
chorion



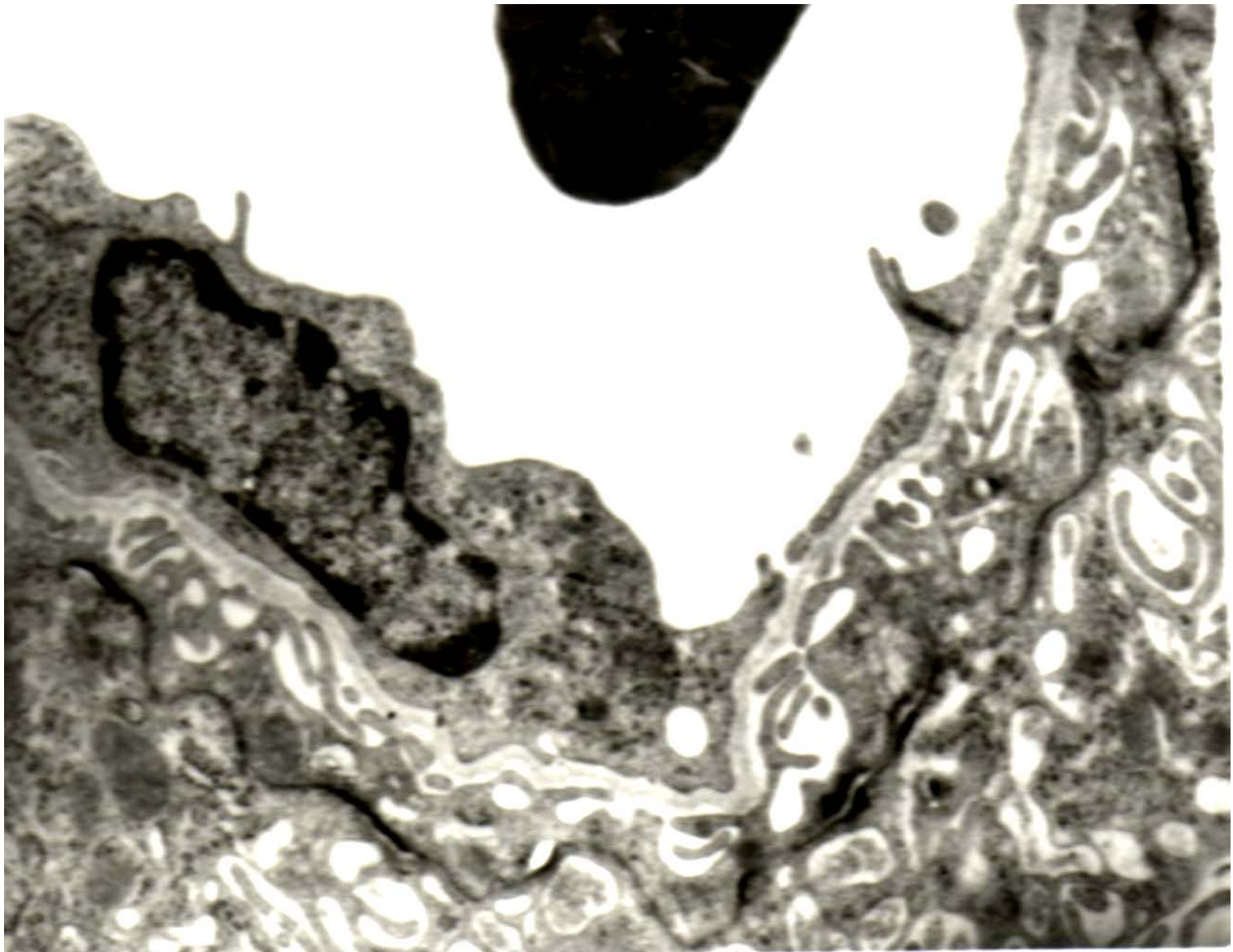
chorion



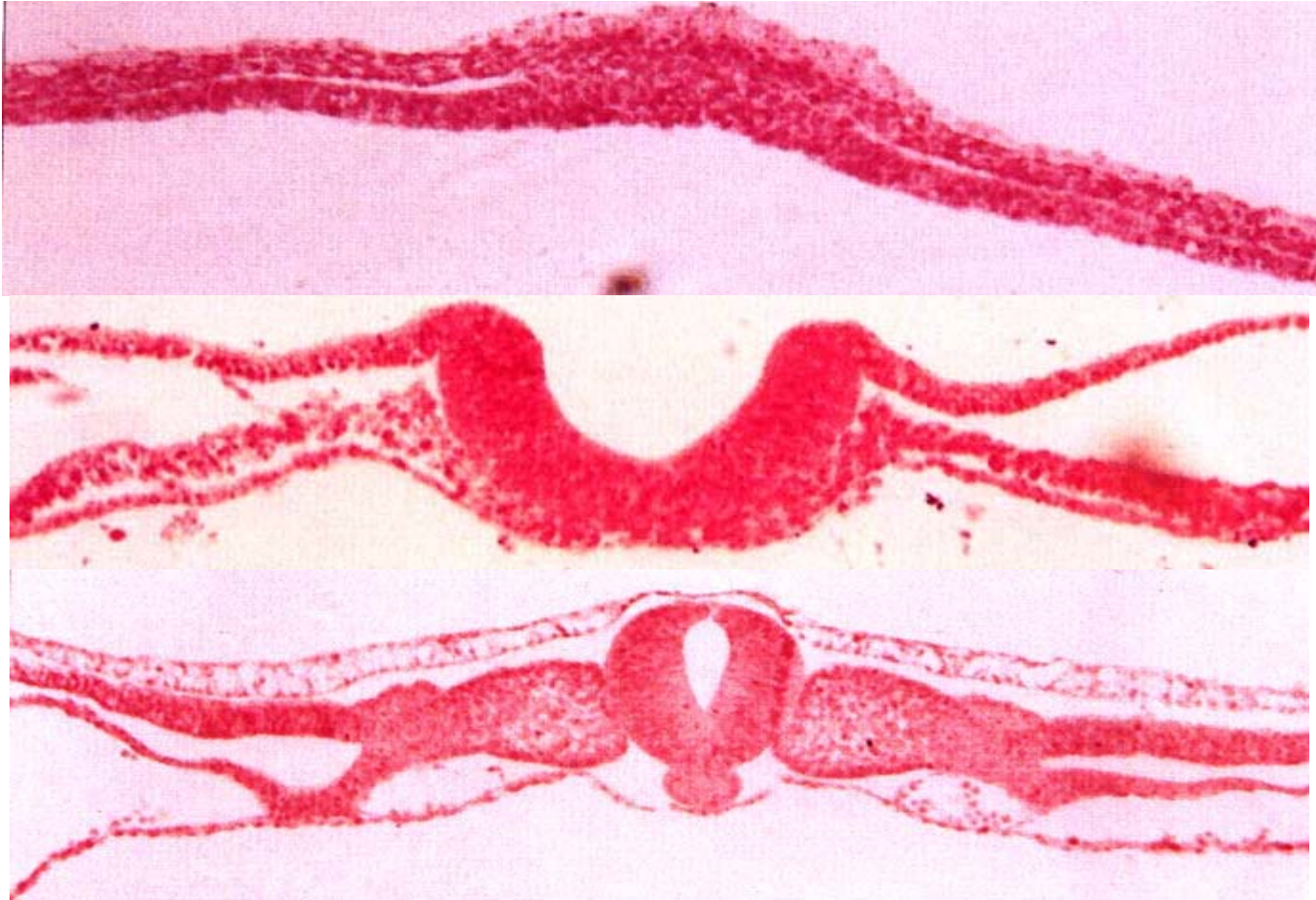chorion



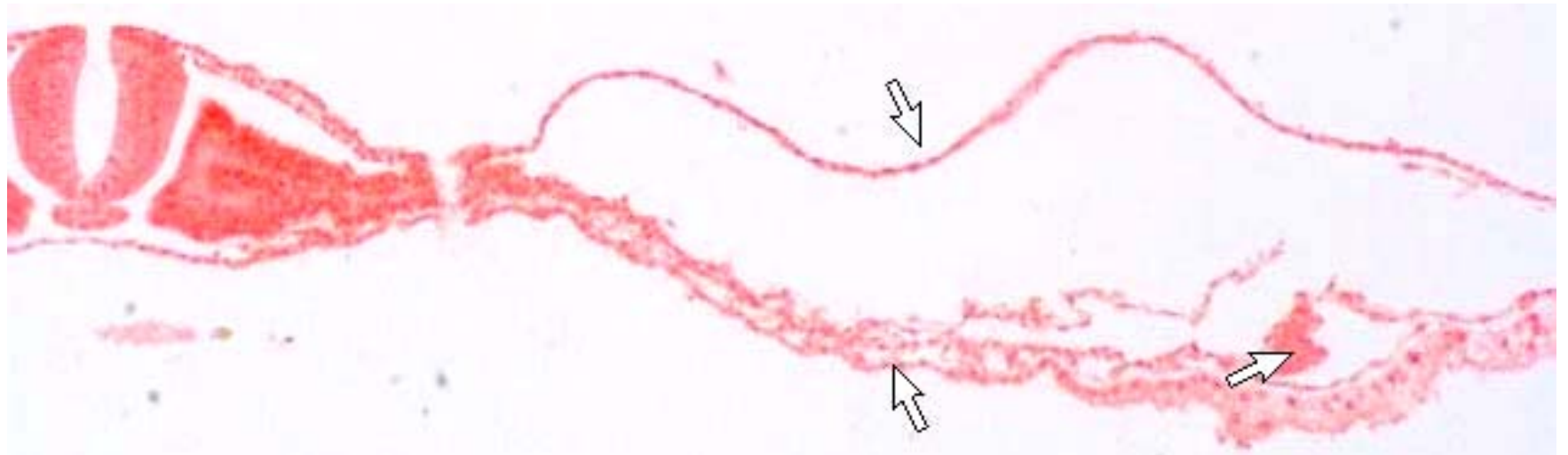
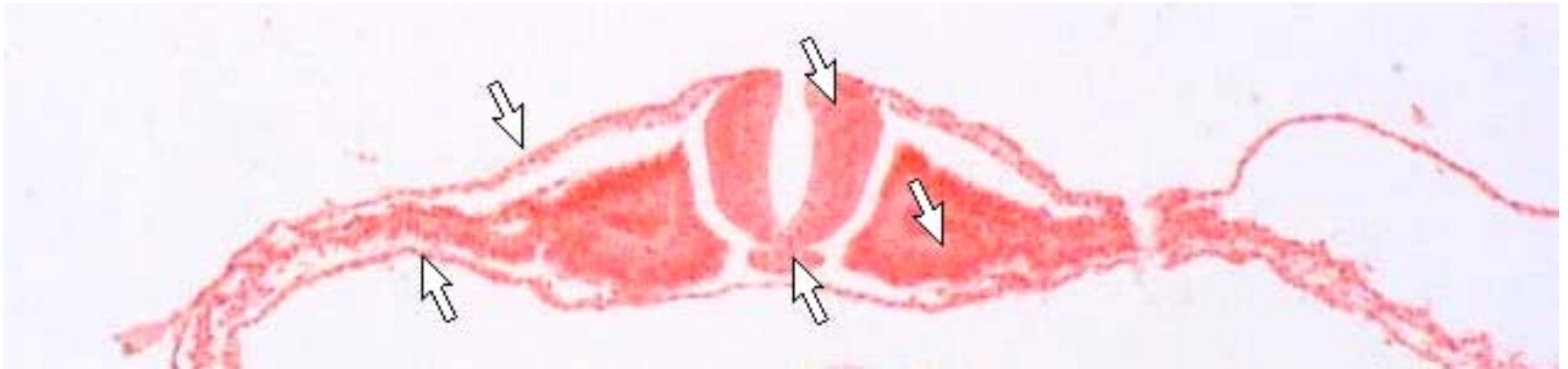
Hofbauer cell



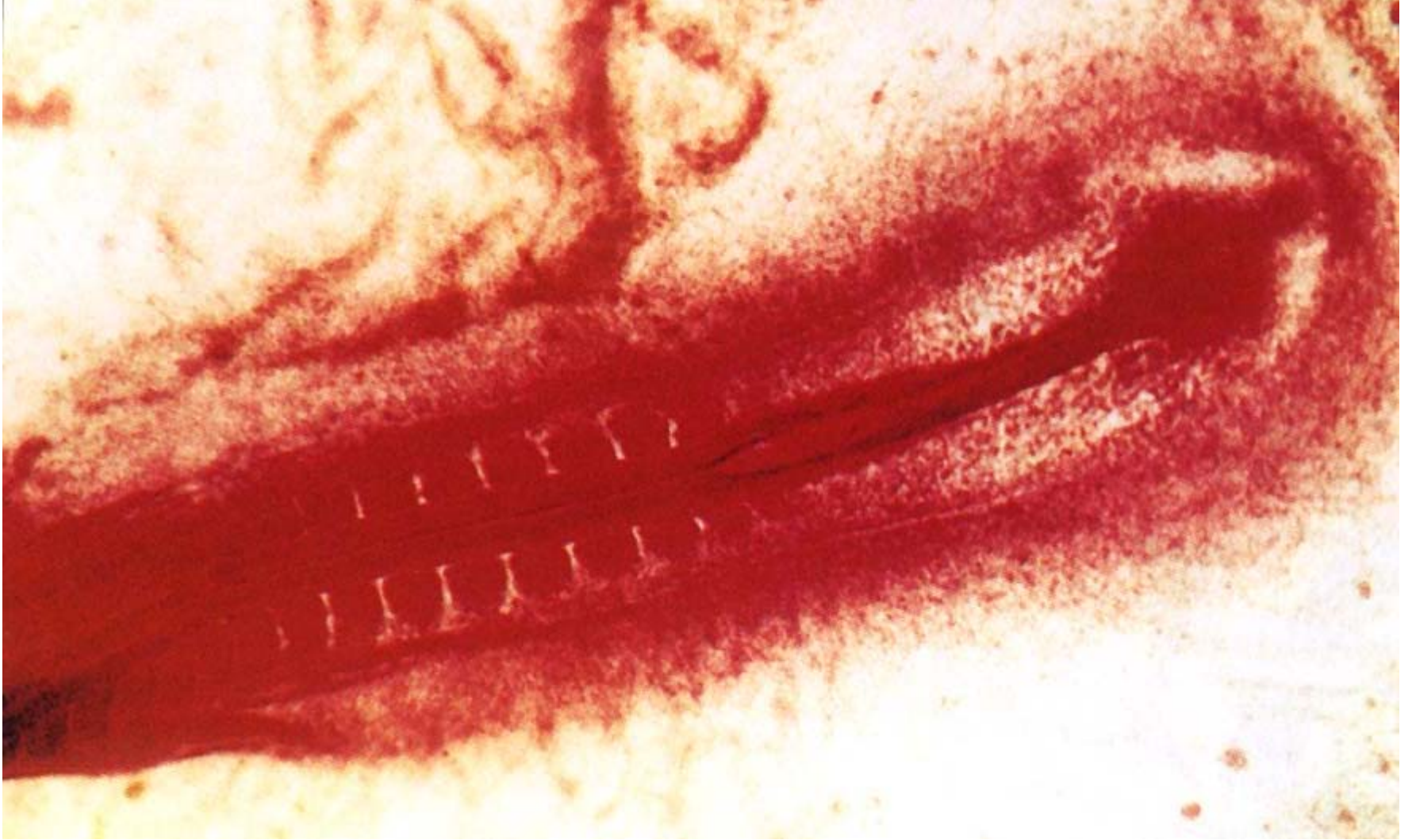
mouse placental barrier



trilaminar germ disc



trilaminar germ disc



somite

IV Summary

- 1 胎盘和胎盘膜的结构与功能
- 2 二胚层胚盘的形成过程
- 3 三个胚层的分化方向